

# REPETITION OF THERAPEUTIC PINNING BY A MENTALLY CHALLENGED: A CASE REPORT AND A MEDICO-LEGAL LESSON LEARNT FROM KATHMANDU MEDICAL COLLEGE AND TEACHING HOSPITAL, KATHMANDU, NEPAL

Barnawal S<sup>1</sup>, Acharya J<sup>2</sup>

## Affiliation

1. Medical officer, Venus Hospital, Kathmandu
2. Assistant Professor, Department of Forensic Medicine, Kathmandu Medical College and Teaching hospital

## ARTICLE INFO

### Article History

Received : 01 August, 2017

Accepted : 14 September, 2017

Published : 31 December, 2017

© Authors retain copyright and grant the journal right of first publication with the work simultaneously licensed under Creative Commons Attribution License CC - BY 4.0 that allows others to share the work with an acknowledgment of the work's authorship and initial publication in this journal.



CR 13

### \* Corresponding Author

Dr. Siddhartha Barnawal

Medical Officer, Venus Hospital  
Kathmandu, Nepal

Email: siddharthabarnawal@gmail.com

## ABSTRACT

We present an unusual case of a 27 year-old-female with undiagnosed mental illness who presented with pricking type of tenderness in and around umbilicus and lower left quadrant of left breast. X-ray revealed the presence of sewing needles on those areas. The foreign body was inserted deliberately by the patient herself on trying to mimic the FNAC procedure performed on her a day before. Under C-arm guidance both the needles were located and extracted. Insertion of foreign body via abdominal wall is the first published report to our knowledge. Performing an invasive procedure in front of a mentally challenged individual requires precaution as a clinician, is an important lesson learned.

## KEY WORDS

Abdominal Wall, Foreign Body, Needle

## Citation

Barnawal S, Acharya J. Repetition of Therapeutic Pinning by A Mentally Challenged: A Case Report and A Medico-legal Lesson Learnt from Kathmandu Medical College and Teaching Hospital, Kathmandu, Nepal BJHS 2017;2(3)4:303-305

## INTRODUCTION

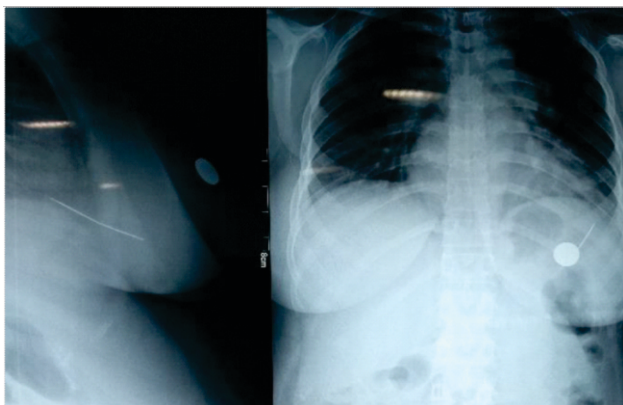
Human body's best defense against penetrating force is skin; subsequently lesser resistance is offered by subcutaneous fat, muscles and blood vessels. As any pointed object penetrates the skin, it continues to slue further with even less force applied, till bone is reached.<sup>1</sup> Any pointed objects like needles, pins etc when inserted accidentally or deliberately into the body causes prick injuries followed by various immediate and late complications. On the other hand; for centuries penetrating events have been used by certified/trained medical practitioners, for remedial and diagnostic procedures like acupuncture, aspiration and injection of drugs/fluids in and out of human body. We present a case report where one of such procedure performed in a mentally challenged patient presented a day later in emergency as complications of a deliberate self-penetrating injury.

## CASE REPORT

A 27 year old female presented on ER with complaints of pricking type tenderness in and around umbilicus and lower quadrant of left breast for few hours. History as given by her father stated that she had undergone an invasive procedure (Fine Needle Aspiration Cytology) for a lump present around her umbilicus. He also added that the patient is only one in the family who has history of multiple episodes of undiagnosed mental illness but failed to provide any medical documents/records about it for perusal by treating medical staffs of emergency department.

On admission her general conditions were fair and vitals were stable. Local examination of peri-umbilical area and left breast revealed no scars or any signs of inflammation. However, on X-ray film, antero-posterior view, taken in erected position, two thin opaque objects with pointed tips, each measuring around 5cm were found to be placed obliquely; one through into the left breast and other near the umbilicus. On lateral view the object in the breast was found to be near the pleural cavity.

Keeping in mind the urgency of the situation, she was advised to undergo fluoroscopy with an aim to locate the needle with more accuracy. Coins were placed as a surface landmark for incision; just above the alleged site of foreign body insertion, over both sites, as revealed in Fig. 1.



**Figure 1:** X-ray films demonstrating position between coin as a surface landmark and foreign objects

Incision was given in the previously marked area around left breast and under C-arm guidance, both the pointed objects were located and extracted. Both objects were noted to be sewing needles. Postoperative recovery was uneventful and she got discharged the next day.

## DISCUSSION

Polyembolokoilamania, a term reported as insertion of foreign objects into natural body orifices mostly by pediatric patients, adults with compromised mental status and at times deliberate insertion via body orifice done for other motives like erotic pleasures and malingering are not new to literature.<sup>2,3</sup> However, in the presented case, sewing needles were not inserted through the orifices, but penetrated through the skin. The chances of these objects sliding into the abdominal cavity or migration and embolisation to deeper body cavities or organs causing lethal outcome cannot be ignored.<sup>4,5</sup> Minimizing intra-operative manipulation was itself a challenge faced by surgeons with fear of complications viz; pneumothorax, hemothorax or sepsis.

Was it patient's luck to have inserted needles confined to subcutaneous tissue, or doctor's fortune to abate medico-legal impediment for taking consent with a mentally challenged to perform invasive procedure initially, still remains unanswered.

## CONCLUSION

Voluntary compliance to any act is consent and an informed written consent form is legal document valid in court of law. Hence, while filling or writing consent for any procedures, it must be clearly understood that the person consenting for any act is in the state of Compos Mentis and that he or she is free from any mental illness and is capable of understanding what is right or wrong for him/her. Any form of consent taken from individual undergoing invasive procedures; like FNAC in our case, must be free from mental ailment and that guardian or caregiver should provide the consent on behalf of a minor or patients with compromised mental status. Extra precautions should be taken by the clinicians performing invasive procedures in mentally challenged, that the procedure is not mimicked by the patients in isolated circumstances.

## CONFLICT OF INTEREST

The authors declare no conflict of interest

## REFERENCES

1. DiMaio VJ, DiMaio D. Wounds caused by pointed and sharp-edged weapons. *Forensic pathology (2nd ed)*. CRC Press;2001:187–212.
2. Ingves MV, Lau T, Fedoroff JP, Levine S. A Man with Urethral Polyembolokoilamania Successfully Treated with Electroconvulsive Therapy. *Archives of sexual behavior* 2014 Aug 1;43(6):1203-7.
3. Unruh BT, Nejad SH, Stern TW, Stern TA. Insertion of foreign bodies (polyembolokoilamania): underpinnings and management strategies. *The Primary Care Companion to CNS Disorders* 2012;14(1).
4. Sutton D, et al. *Textbook of Radiology and imaging (6th ed)*. Vol 2. Churchill Livingstone;1998:1394–1395.
5. Aktimur R, Cetinkunar S, Kucuk OG. Self-inserted Sewing Needles Through the Abdominal Wall: Is the Laparoscopic Approach with Omentectomy a Feasible Option?. *Clin Surg* 2016;1:1:1029ian *Journal of Emergency Medicine*. 2014; 16(2), 164-170.